

COMPLETE REPAIR FOR TETRALOGY OF FALLOT IN CHILDREN: SHORT-TERM OUTCOME IN A SINGLE CENTER

Le Thanh Khanh Van¹, Hoang Ngoc Vi², Doan Van Phung³, Bui Quoc Thang^{4*}

Abstract – *Tetralogy of Fallot is a common cyanotic congenital heart disease. Early surgery treatment gives patients a chance to have normal physical and mental health due to preventing complications of cyanosis and even death as a natural history of tetralogy of Fallot. This study aimed to show short-term outcomes (including the time of postoperative hospital stay and 30 days after discharge) of tetralogy of Fallot complete repair at the Department of Pediatric Cardiac Surgery, Cho Ray Hospital. A retrospective study was performed on the data of medical documents of 38 patients, who underwent complete repair for tetralogy of Fallot with full sternotomy and cardiopulmonary bypass from March 2017 to December 2019, following a collection form. The results showed the average age and weight were 33.89 ± 13.02 months and 11.77 ± 2.48 kg. The cardiopulmonary bypass time was 147.74 ± 12.48 mins, the aortic cross-clamp time 104.84 ± 9.73 mins, the mechanical ventilation time 31.14 ± 10.75 hours, the duration of stay in the intensive care unit 58.03 ± 13.56 hours, the postoperative hospital stay time 10.12 ± 1.5 days, and the mortality rate 2.6%. The study concludes that the short-term surgical outcome of complete repair for tetralogy of Fallot in lightweight children is safe and effective with a low mortality rate.*

Keywords: *complete repair for tetralogy of Fallot, mortality rate, short-term surgical outcome.*

I. INTRODUCTION

Tetralogy of Fallot (TOF) is one of the most common cyanotic congenital heart diseases, which accounts for about 3.3 in 10,000 live

births. Anatomically, TOF is a combination of four defects of the heart and the pulmonary artery, including the right ventricular outflow tract obstruction (RVOTO) or the narrowing of the pulmonary valve and main pulmonary artery (MPA), the malalignment ventricular septal defect (VSD), the overriding aorta or the aortic valve sits directly on top of VSD and seems to open from both ventricles, and the right ventricular hypertrophy. The early surgery for TOF was a palliative treatment performed by Alfred Blalock in 1944 that created a systemic to pulmonary shunt. In 1954, Kirlin performed the complete repair of all defects of TOF using cross-circulation [1].

Children with TOF have to perform reparative surgery as soon as possible to prevent the complications of cyanosis and even death due to natural history, and this early fixing makes them grow normally in both physical and mental health. The procedure of complete repair for TOF recently includes VSD closure and RVOTO reconstruction with cardiopulmonary bypass (CPB) support. The RVOTO reconstruction is the most important technique, and it varies between patients, mainly depending on the position of obstruction and the right ventricle outflow structure after reconditioning affects the surgical outcome directly. Some current techniques for RVOTO reconstructing include muscular resection, valvotomy, augmentation of the pulmonary artery with autograft, biologic or artificial patch, and pulmonary valve plasty.

The aim of this study was to evaluate the clinical and paraclinical characteristics and to show the short-term surgical outcome (including the time of postoperative hospital stay and 30 days after discharge) of TOF complete repair at the Department of Pediatric Cardiac Surgery within Cho Ray Hospital, Vietnam, to provide reliable information and support further research.

^{1,2,3,4}Cho Ray Hospital, Ho Chi Minh City, Vietnam

*Corresponding author: buiquocthang.vn@gmail.com

Received date: 08th June 2022; Revised date: 04th August 2022; Accepted date: 20th September 2022

II. LITERATURE REVIEW

The long-term survival rate of TOF repair has significantly improved with over 90% surviving after 10 years, and the short-term surgical outcome has decreased early mortality in recent eras compared to the last two decades (Figure 1). The early mortality rate of congenital cardiothoracic surgery was reported under 3% in recent years. However, the pre-operative severity of the TOF (including the size of the pulmonary valve and pulmonary arteries, which were described by Z-score, the right ventricle-pulmonary artery pressure gradient, and oxygen saturation) and other residual problems of peri-operation (such as right ventricular dysfunction, pulmonary regurgitation, pulmonary blood flow, residual RVOTO and VSD, and arrhythmia) may affect the short-term surgical outcome [2–11].

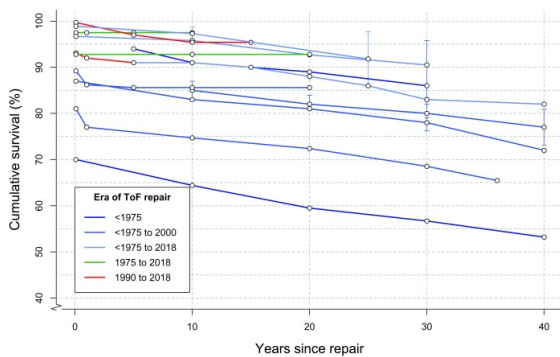


Fig. 1: Survival following tetralogy of Fallot (TOF) repair [2]. Survival at 10 years ranges from 68.5% to 90.5%

III. RESEARCH METHODS

A retrospective study of patients who underwent complete repair of TOF was conducted at the Department of Pediatric Cardiac Surgery within the Cardiovascular Center at Cho Ray Hospital from March 2017 to December 2019. The TOF was diagnosed by echocardiography and a contrast chest CT scan. The protocol of TOF complete repair includes full midline sternotomy, using CPB supporting, arresting the heart by aortic cross-clamp and anterograde cardioplegia, maintaining intraoperative temperature ranges 30°C – 32°C , RVOTO reconstruction

and VSD closure, which was performed via transatrial-transpulmonary approach.

Preoperative data included age, weight, gender, baseline oxygen saturation by pulse oximetry (SpO₂), McGoon index calculation, transpulmonary pressure gradient and Z-score of the pulmonary annulus (PA), which were evaluated by echocardiography. Operative variables including CPB time, ACC time, surgical protocol, transpulmonary pressure gradient and RV/LV pressure were directly measured and calculated. Postoperative variables included the mechanical ventilation time, the length of ICU and postoperative hospital stay, the baseline SpO₂, the complications consisting of pleural or pericardial effusion, heart arrhythmias, low cardiac output syndrome (LCOS), right ventricular failure, pneumonia, residual VSD, residual RVOTO, septic shock, and death. Short-term surgical outcome was defined as the time of postoperative hospital stay and the mortality rate at 30 days after discharge. STATA version 14 was used for data analysis. Standard descriptive statistical methods were used and the results were described as frequencies or medians with ranges, as appropriate.

IV. RESULTS AND DISCUSSION

A. Research results

The data of 38 patients (24 males and 14 females) were collected in this report from their medical documents. The age at surgery was 33.89 ± 13.02 months old, ranging from 2 to 150 with a median of 13.5 months. The weight at surgery was 11.77 ± 2.48 kg, ranging from 5 to 34 with a median of 9 kg.

The data on preoperative characteristics showed that 7 patients had received prior interventions, consisting of 4 patients with modified Blalock-Taussig shunt, 2 patients with patent ductus arteriosus (PDA) stenting and 1 patient with RVOTO stenting. The average baseline SpO₂ was $82 \pm 3\%$ and 4 patients were more than 95%. The Z-score of PA and MPA were under -2.

There were many different surgical techniques for RVOTO plasty, and three patients were performed monocusp valve placement (Table 2).

All patients were not cyanotic after complete repair with the SpO₂ being more than 95%. Three

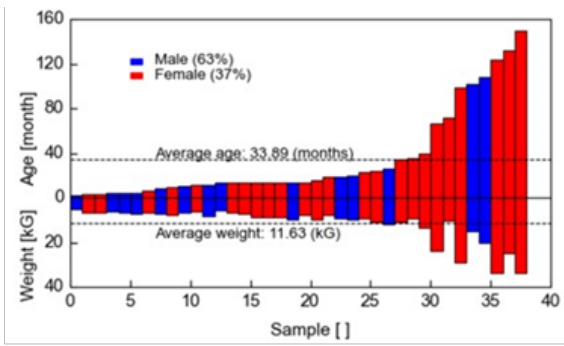


Fig. 2: The age and weight of 38 patients (from younger to older)

Table 1: Preoperative characteristics of patients with TOF

Characteristics	Results
Baseline oxygen saturation (%)	82±3% (min. 59% – max. 98%)
Overriding aorta (%)	39±3.2% (min. 25% – max. 50%)
Transpulmonary pressure gradient (mmHg)	91.73±9.18 mmHg (min. 32 mmHg – max. 160 mmHg)
McGoon index	1.8± 0.21
PA Zscore	-2.88±0.76
MPA Zscore	-2.51±0.85
Other cardiac defects (number of patients)	Patent foramen ovale (PFO): 17 Patent ductus arteriosus (PDA): 6 Left superior vena cava: 2 Atrial septal defect: 2

patients suffered from ventricular premature beats but the condition was ceased by medication. One patient died on the 9th day postoperatively because of sepsis shock and organ dysfunction. No patient was re-admitted to the hospital after 30 days discharge. Pneumonia, pleural and pericardial effusion were the common complications. One patient stayed in the hospital for 30 days postoperatively due to the recurrent pleural effusion of both the left and right lungs. Two patients with residual problem (1 residual RVOTO and 1 residual VSD) were confirmed by echocardiography on the day before hospital discharge (Table 3).

B. Discussion

Tetralogy of Fallot is one of the frequent forms of complex congenital heart diseases that requires early surgery. Complete repair has been performed in many pediatric cardiac surgery centers

recently, and while this technique still challenges the surgeon especially in lightweight patients, age was not a risk factor for mortality or reoperation [4].

In our study, 7 children underwent prior palliative interventions and not complete repair at initial diagnosis. The PA size, younger age and clinical conditions were common factors that contributed to the need to perform palliative intervention instead of complete repairs, such as creating an aortopulmonary shunt, PDA stenting or RVOTO stenting. These strategies of palliation increased pulmonary blood flow just in selected patients, and they then were followed up for complete repair operation [2]. Each type of palliation should be applied for each specific situation [5–7].

The common additional defect of TOF was patent foramen ovale (PFO) [8]. It did not require considerable time for PFO closing in the operation. In some specific situations, such as severe right ventricle (RV) failure or RVOTO, the surgeon decided not to close the PFO as a way to save the patient. Preoperative transpulmonary pressure gradient was too high, with Z-scores of PA and MPA of -2.88 and -2.51, respectively. These results indicated that severe stenosis in RVOTO may cause RV failure, especially prolonging it to adulthood [8].

McGoon ratio or Nakata index was used to predict the postoperative prognosis. An optimal McGoon ratio (1.8) in this study was the predictor of a low mortality rate.

Muscle resection, pulmonary valvotomy and MPA augmentation were the common surgical techniques of RVOTO reconstruction. Monocusp was an alternative for these patients. Many studies show that there is an insignificant difference between transannular patch and monocusp in the surgical outcome, but the high frequency of postoperative pulmonary regurgitation of the transannular patch makes monocusp a preferred technique [4, 9, 10]. However, patients with monocusp have to use anticoagulant or antiplatelet postoperatively and require other operations when this artificial valve becomes inappropriate. There were 3 patients with premature ventricular beat. Muscle resection of VSD closure and infundibular septal muscle were the main

Table 2: Intraoperative characteristics of patients with TOF

Characteristics		Results
CPB time (min)		147.74±12.48 mins (min. 73 mins – max. 275 mins)
ACC time (min)		104.84±9.73 mins (from 50 mins to 165 mins)
Transpulmonary pressure gradient (mmHg)		15.59±4.54 mmHg (min. 1 mmHg – max. 62 mmHg)
Pressure RV/LV		0.60±0.05 (0.34 – 0.91)
RVOTO repair (number of patients)	Muscle resection	36
	Valvotomy	29
	MPA augmentation	25
	Branch augmentation	4
	Monocusp	3
	Infundibular patch	1

Table 3: Postoperative characteristics of patients with TOF

Characteristics		Results
Mechanical ventilation time (hour)		31.14±10.75 hours (min. 7.5 hours – max. 196 hours)
ICU length of stay (hour)		58.03±13.56 hours (min. 13 hours – max. 196 hours)
Postoperative hospital length of stay (day)		10.12±1.5 days (min. 5 days – max. 30 days)
Complications (number of patients)	None	12
	Pneumonia	11
	Pleural effusion	18
	Pericardial effusion	8
	Arrhythmias	Ventricular premature beat 3
	RV failure and LCOS	12
	Death	1
	Residual VSD	1
	Residual RVOTO	1
SpO2 postoperation ≥ 95%		38
Re-admission (30 days after discharge)		0

parts of resection, and the surgeon sometimes had to remove some tissue of the ventricular septum below the infundibulum that was considered obstructing RVOTO. This resection may lead to temporarily or permanently AV block.

Residual RVOTO and VSD are the two common complications in the immediate postoperative period [11]. In this study, the transpulmonary pressure gradient measured after CPB weaning was 15.59 and the postoperative pressure ratio between RV and LV was 0.6. Both of them predicted a good postoperative prognosis with a low rate of residual RVOTO obstruction. As a result of low residual RVOTO and VSD rates, no patients in this study needed to undergo reoperation during the short-term period.

RV failure and LCOS were the severely complicated characteristics of TOF repair. If they were not managed well, organ failure could be induced and threaten patient’s life [12].

Pericardial effusion and pleural effusion in

normal circumstances may prolong hospital length of stay, especially in case of recurrence. The mortality rate of complete repair for TOF in many current reports was about 1 – 5% [3, 4]. The low mortality rate in this study (2.6%) may be partly because of the optimal McGoon ratio, no early reoperation, no AV block and well-controlling of RV failure and LCOS. The limitation of this study was not to show the data on mid-term and long-term surgical outcomes so there was not enough evidence to make long-term conclusions about the success of the complete repair technique.

V. CONCLUSION AND RECOMMENDATIONS

TOF treatment by complete repair requires an effective cardiovascular surgical team for diagnostic and follow-up in peri-operation, especially in lightweight children. Early surgical outcome

of patients with TOF complete repair in the Department of Pediatric Cardiac Surgery at Cho Ray Hospital has been shown to be satisfactory with a low mortality rate. However, more clinical data with a larger number of patients is needed to figure out which factors affect to these results.

REFERENCES

- [1] Jacobs ML, Jacobs JP. The early history of surgery for patients with tetralogy of Fallot. *Cardiology in The Young*. 2008;18(S3): 8–11.
- [2] Van der Ven JPG, Van den Bosch E, Bogers A, Helbing WA. Current outcomes and treatment of tetralogy of Fallot. *F1000Research*. 2019;8(F1000 Faculty Rev):1530 Available from: DOI: 10.12688/f1000research.17174.1.
- [3] BBailey J, Elci OU, Mascio CE, Mercer-Rosa L, Goldmuntz E. Staged versus complete repair in the symptomatic neonate with tetralogy of Fallot. *The Annals of Thoracic Surgery*. 2020;109(3): 802–808.
- [4] Park CS, Lee JR, Lim HG, Kim WH, Kim YJ. The long-term result of complete repair for tetralogy of Fallot. *European Journal of Cardio-thoracic Surgery*. 2010;38(3): 311–317.
- [5] Wilder TJ, Van Arsdell GS, Benson L, PhamHung E, Gritti M, Page A, et al. Young infants with severe tetralogy of Fallot: Early primary surgery versus transcatheter palliation. *The Journal of Thoracic and Cardiovascular Surgery*. 2017;154(5): 1692–1700.
- [6] Quandt D, Ramchandani B, Stickley J, Mehta C, Bhole V, Barron DJ, et al. Stenting of the right ventricular outflow tract promotes better pulmonary arterial growth compared with modified Blalock-Taussig shunt palliation in tetralogy of Fallot-Type lesions. *JACC: Cardiovascular Interventions*. 2017;10(17): 1774–1784.
- [7] Bentham JR, Zava NK, Harrison WJ, Shauq A, Kalantre A, Derrick G, et al. Duct stenting versus modified Blalock-Taussig shunt in neonates with duct-dependent pulmonary blood flow: Associations with clinical outcomes in a multicenter national study. *Circulation*. 2018;137(6): 581–588.
- [8] Younis Memon MK, Akhtar S, Mohsin M, Ahmad W, Arshad A, Ahmed MA. Short and midterm outcome of Fallot's tetralogy repair in infancy: A single center experience in a developing country. *Journal of Ayub Medical College Abbottabad*. 2019;31(3): 383–387.
- [9] Dyamenahalli U, McCrindle BW, Barker GA, Williams WG, Freedom RM, Bohn DJ. Influence of perioperative factors on outcomes in children younger than 18 months after repair of tetralogy of Fallot. *The Annals of Thoracic Surgery*. 2000;69(4): 1236–1242.
- [10] Singh NM, Loomba RS, Gudausky TM, Mitchell ME. Monocusp valve placement in children with tetralogy of Fallot undergoing repair with transannular patch: A functioning pulmonary valve does not improve immediate postsurgical outcomes. *Congenital Heart Disease*. 2018;13(6): 935–943.
- [11] Chittithavorn V, Rergkliang C, Chetpaophon A, Vasinanukorn P, Sopontammarak S, Promphan W. Predicted outcome after repair of tetralogy of Fallot by postoperative pressure ratio between right and left ventricle. *Journal-Medical Association of Thailand*. 2006;89(1): 43–50.
- [12] Cullen S, Shore D, Redington A. Characterization of right ventricular diastolic performance after complete repair of tetralogy of Fallot: restrictive physiology predicts slow postoperative recovery. *Circulation*. 1995;91(6): 1782–1789.

